Epidermolysis Bullosa 32

Jo-David Fine and Jemima E. Mellerio

Synonyms: ■ All forms of EB: EB hereditaria ■ EB simplex: epidermolytic EB ■ Junctional EB: EB atrophicans, EB letalis ■ Dystrophic EB: EB dystrophica

Key features

- Epidermolysis bullosa (EB) encompasses multiple clinically distinctive disorders that share three major features: genetic transmission, mechanical fragility of the skin, and blister formation
- There are four major forms of inherited EB – EB simplex, junctional EB, dystrophic EB, and Kindler EB – which differ in the ultrastructural site within which cutaneous blisters form
- EB may be diagnosed by immunofluorescence antigenic mapping, transmission electron microscopy, or genetic analysis
- Any epithelial-lined or epithelial-covered organ is at potential risk for involvement in the more severe forms of inherited EB
- In the absence of specific therapy, management is primarily focused on prevention of blisters, wound care, and treatment of extracutaneous complications

INTRODUCTION

Inherited epidermolysis bullosa (EB), the prototypic mechanobullous disease, is characterized by the development of blisters following seemingly minor or insignificant trauma or traction to the skin[1,2]. The most recent classification includes four major forms of classic EB – EB simplex, junctional EB, dystrophic EB, and Kindler EB – and at least 30 distinctive clinical phenotypes[1] (Table 32.1). Inherited EB can result from mutations within the genes that encode at least 16 structural proteins: keratins 5 and 14; the subunits of laminin 332 (formerly laminin 5); types VII and XVII collagens; plectin; $\alpha_6\beta_4$ integrin; α_3 integrin subunit; bullous pemphigoid antigen 1; kindlin-1; exophilin 5; kelch-like protein 24; and CD151 (tetraspanin 24). The current EB classification also delineates other disorders associated with skin fragility in which blistering is a relatively minor feature, with at least 23 additional genes implicated in their pathogenesis[1]. These entities include several disorders that were previously classified as suprabasal forms of EB simplex, such as acral peeling skin syndrome (transglutaminase-5; see Table 57.8), skin fragility–ectodermal dysplasia syndrome (plakophilin-1), and acantholytic erosive disorder (desmoplakin or plakoglobin).

Although most forms of EB are rare, research into their underlying pathophysiologic bases has led to major advances in our understanding of the cell and molecular biology of keratins, other keratinocyte-associated structural proteins, collagens, and the cutaneous extracellular matrix (ECM). Study of EB has also helped to elucidate mechanisms of epithelial cell adhesion, migration, and differentiation and to highlight the role of the epidermal basement membrane in health and disease. The creation of *in vitro* and animal models of EB has facilitated the development of novel translational therapeutic approaches for the treatment of EB patients[2].

HISTORY

Epidermolysis bullosa was first described in 1870 by von Hebra under the name "erblichen pemphigus"[3]. Its current name, "epidermolysis bullosa hereditaria", was coined by Koebner in 1886. Hallopeau recognized the distinct clinical features of simplex and dystrophic forms of EB in 1898. Junctional EB was first identified in 1935 by Herlitz and termed "EB letalis". Precise characterization of these three major EB types via the use of transmission electron microscopy was first achieved by Pearson in 1962[4]. In the ensuing years, additional EB phenotypes were described. Monoclonal antibody studies provided the first suggestion that specific protein defects underlie individual types and subtypes of this disease[5–8]. In 1986, the National EB Registry was established in the US by the National Institutes of Health, facilitating epidemiologic, clinical, and laboratory characterization of each major EB type and subtype[9,10]. In 1991, Bonifas et al.[11] utilized linkage analysis to demonstrate the molecular basis for EB simplex. Subsequent work by others has established the precise molecular basis for most of the EB subtypes recognized to date.

EPIDEMIOLOGY

Based on National EB Registry data[12,13], the estimated overall prevalence and incidence of EB in the US are 11.1 per 1 million population and 19.6 per 1 million live births, respectively. Carrier frequencies have also been reported[14]. The approximate prevalences and incidences, respectively, of the major types of EB are as follows: EB simplex, 6.0 and 7.9; junctional EB, 0.5 and 2.7; dominant dystrophic EB, 1.5 and 2.1; and recessive dystrophic EB, 1.4 and 3.0.

PATHOGENESIS

EB is caused by mutations within genes that encode structural proteins that reside within the epidermis (EB simplex), dermal–epidermal junction (junctional EB), or uppermost papillary dermis (dystrophic EB). The site within which each of these proteins resides determines the ultrastructural location where the blisters arise (Fig. 32.1, see Table 32.1).

EB Simplex

The most common forms of EB simplex (EBS) are transmitted in an autosomal dominant manner and are associated with blistering at the level of the basal keratinocyte. EBS most often results from a dominant-negative mutation (see Ch. 54) within the keratin 5 (*KRT5*) or 14 (*KRT14*) genes, expression of which is primarily within the basal layer of the epidermis[15,16]. The clinical severity and other phenotypic features of EBS are closely associated with the genotype. For example, mutations in the helix initiation and termination motifs of *KRT5* and *KRT14* lead to the severe subtype of EBS (severe EBS, previously known as EBS-Dowling–Meara), whereas the specific phenotype of EBS with mottled pigmentation almost always arises from a particular missense mutation in the V1 domain of *KRT5*.

Dominant stabilizing mutations in the kelch-like protein 24 ubiquitin ligase gene (*KLHL24*) lead to EBS via increased ubiquitination and degradation of keratin 14[17]. An autosomal recessive form of EBS due to mutations in the gene encoding plectin (*PLEC*) is associated with muscular dystrophy, which is not surprising considering that plectin is expressed in skeletal muscle as well as in the hemidesmosomes of basilar keratinocytes. Other EBS patients with plectin or rarely $\alpha_6\beta_4$ integrin deficiencies present with pyloric atresia, while autosomal recessive variants of EBS caused by mutations in bullous pemphigoid antigen 1/dystonin (*DYS*) or exophilin 5 (*EXPH5*) genes have also been reported.

Junctional EB

Junctional EB (JEB) is almost always transmitted in an autosomal recessive manner (see Table 32.1). The severe subtype of JEB (severe JEB,

Downloaded for Anonymous User (n/a) at Egyptian Knowledge Bank from ClinicalKey.com by Elsevier on March 10, 2024. For personal use only. No other uses without permission. Copyright ©2024. Elsevier Inc. All rights reserved.

CLASSIC EPIDERMOLYSIS BULLOSA: SIMPLEX, JUNCTIONAL, DYSTROPHIC, AND KINDLER SUBTYPES		
Subtype	**Inheritance**	**Defective protein(s)**
Intraepidermal cleavage		
EBS, localized (formerly Weber–Cockayne)	AD	Keratins 5 and 14
EBS, severe (formerly Dowling–Meara)		
EBS, intermediate		
EBS with mottled pigmentation	AD	Keratin 5
EBS, migratory circinate		
EBS, intermediate or severe, AR	AR	Keratins 5 and 14
EBS, intermediate (formerly Ogna)	AD	Plectin
EBS, intermediate with muscular dystrophy	AR	Plectin
EBS, severe with pyloric atresia	AR	Plectin; $\alpha_6\beta_4$ integrin
EBS, intermediate with cardiomyopathy	AD	Kelch-like protein 24
EBS, localized or intermediate	AR	Bullous pemphigoid antigen 230 (BP230); exophilin 5
EBS, localized with nephropathy	AR	CD151 (tetraspanin 24)
Intra-lamina lucida cleavage		
JEB, severe (formerly Herlitz)	AR	Laminin 332
JEB, intermediate	AR*	Laminin 332; collagen XVII
JEB with pyloric atresia	AR	$\alpha_6\beta_4$ integrin
JEB, late onset	AR	Collagen XVII
JEB with interstitial lung disease and nephrotic syndrome	AR	α_3 integrin subunit
JEB, localized	AR	Laminin 332; collagen XVII; $\alpha_6\beta_4$ integrin; α_3 integrin subunit
JEB, inversa	AR	Laminin 332
JEB-laryngo-onycho-cutaneous syndrome	AR	Laminin α3 chain (a isoform)
Sublamina densa cleavage		
DDEB, intermediate	AD	Collagen VII
DDEB, localized†		
DDEB, pruriginosa		
DDEB, self-improving		
RDEB, severe (formerly Hallopeau–Siemens)	AR	
RDEB, intermediate		
RDEB, inversa		
RDEB, localized†		
RDEB, pruriginosa		
RDEB, self-improving		
Mixed cleavage planes		
Kindler EB	AR	Fermitin family homolog-1 kindlin-1

*One case with AD inheritance has been reported.
†Includes variants previously referred to as pretibial (DDEB & RDEB), acral (DDEB), and nails only (DDEB).

Table 32.1 Classic epidermolysis bullosa (EB): simplex, junctional, dystrophic subtypes, and Kindler EB. Entities in **bold** are the more common subtypes, and those with a darker background represent syndromic variants. AD, autosomal dominant; AR, autosomal recessive; EBS, epidermolysis bullosa simplex; DDEB, dominant dystrophic EB; RDEB, recessive dystrophic EB.

previously known as JEB-Herlitz) typically results from homozygous or compound heterozygous truncating mutations within a gene encoding one of the three subunits of laminin 332, a key component of the lamina lucida of the dermal–epidermal junction (see Ch. 28)[18]. In laryngo-onycho-cutaneous syndrome, the underlying mutations affect only the A isoform of the laminin α3 subunit. The milder intermediate form of JEB (intermediate JEB, previously known as JEB-non-Herlitz and generalized atrophic benign EB) results from mutations within the genes for either a subunit of laminin 332 or, less frequently, type XVII collagen/bullous pemphigoid antigen 2. JEB with pyloric atresia, which is much more common than EBS with pyloric atresia, is also caused by mutations within either of the two genes that encode the subunits of $\alpha_6\beta_4$ integrin. A form of JEB associated with respiratory and renal involvement results from mutations in the integrin α_3 chain.

Dystrophic EB

Dystrophic EB (DEB) is transmitted in either an autosomal dominant or autosomal recessive manner and is caused by mutations in the type VII collagen gene (*COL7A1*). Dominant DEB (DDEB) results from dominant-negative mutations, typically a missense mutation that leads to substitution of another amino acid for a glycine within the triple-helical domain of this collagen. Although the resultant protein is structurally abnormal, immunohistochemical staining for type VII collagen along the dermal–epidermal junction is usually indistinguishable from that of normal skin.

Recessive DEB (RDEB) is due to compound heterozygous or, less frequently, homozygous mutations within the type VII collagen gene[19–21]. Premature stop codons, which result in truncated proteins, are

Downloaded for Anonymous User (n/a) at Egyptian Knowledge Bank from ClinicalKey.com by Elsevier on March 10, 2024. For personal use only. No other uses without permission. Copyright ©2024. Elsevier Inc. All rights reserved.

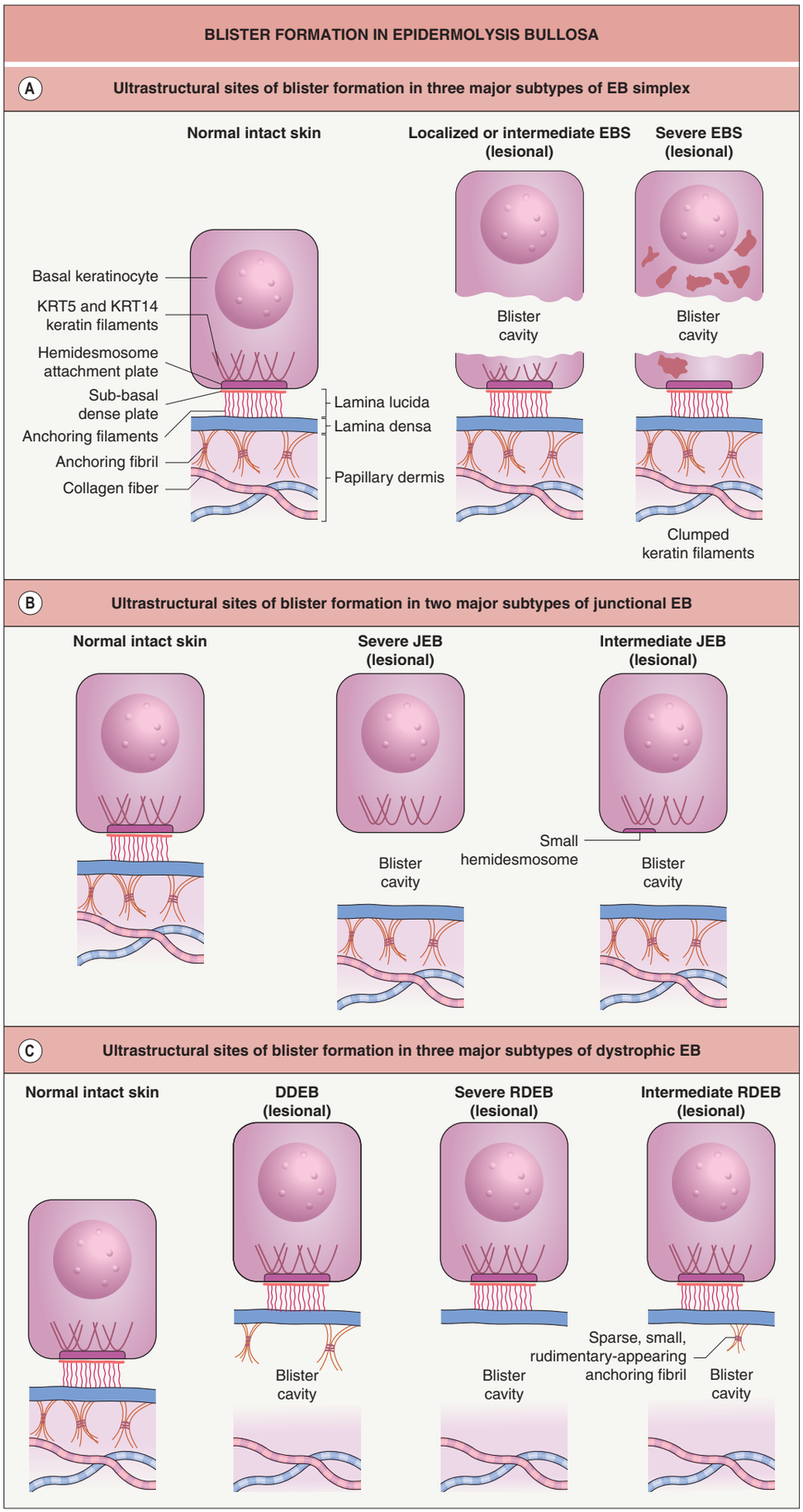

Fig. 32.1 Blister formation in epidermolysis bullosa (EB). A Ultrastructural sites of blister formation in three major subtypes of *EB simplex (EBS)*. The ultrastructure of normal intact skin is presented for comparison. In all three major subtypes of EBS – localized, intermediate, and severe – blisters arise within the lowermost intracytoplasmic portion of the basilar keratinocyte. In severe EBS, keratin filaments tend to coalesce into larger electron-dense clumps, especially in lesional skin. Keratin filaments are absent or reduced in the rare autosomal recessive form of EBS, and in EBS with muscular dystrophy there is lack of integration of keratin filaments into the underlying hemidesmosome. **B** Ultrastructural sites of blister formation in two major subtypes of *junctional EB (JEB)*. All forms of JEB are characterized by blister formation within the lamina lucida of the dermal–epidermal junction. As such, the lamina densa remains firmly attached to the dermis which forms the base of the blister cavity. Sub-basal dense plates and anchoring filaments are absent in generalized severe JEB and often attenuated in other subtypes of JEB. Hemidesmosomes are absent or extremely sparse and rudimentary in severe JEB, whereas they are normal or reduced in number and size in intermediate JEB. **C** Ultrastructural sites of blister formation in three major subtypes of *dystrophic EB (DEB)*. Blister formation occurs beneath the lamina densa in all forms of dystrophic EB. Anchoring fibrils appear normal in size and structure in dominant DEB (DDEB) skin, although they may be somewhat reduced in number. Consistent with the presence of sublamina densa cleavage, these anchoring fibrils remain attached to the blister roof, which is composed of intact epidermis and an attached basement membrane that includes the lamina densa. In contrast, anchoring fibrils are usually completely absent in lesional skin from patients with severe recessive DEB (RDEB). In intermediate RDEB, anchoring fibrils are reduced in number and rudimentary in appearance.

Downloaded for Anonymous User (n/a) at Egyptian Knowledge Bank from ClinicalKey.com by Elsevier on March 10, 2024. For personal use only. No other uses without permission. Copyright ©2024. Elsevier Inc. All rights reserved.

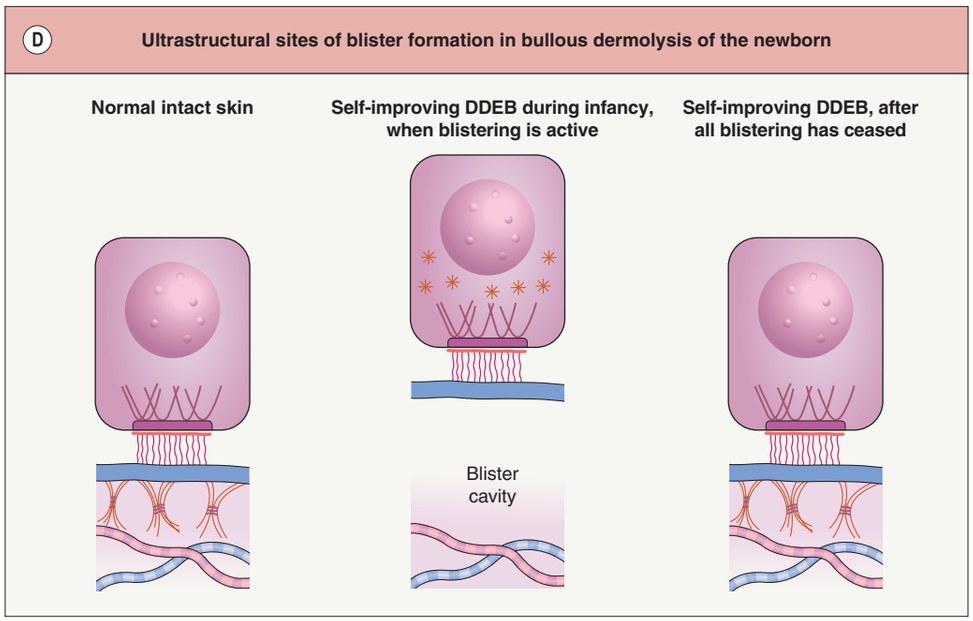

Fig. 32.1 Blister formation in epidermolysis bullosa (EB). (cont'd) D Ultrastructural site of blister formation in the form of DEB referred to as *self-improving DEB*. With age, there is improvement in the transport and deposition of type VII collagen from the keratinocyte cytoplasm to the anchoring fibrils of the basement membrane.

characteristic of the severe subtype (severe RDEB, previously known as RDEB-Hallopeau–Siemens). Consistent with the severity of these mutations, anchoring fibrils are undetectable or extremely sparse and poorly formed in skin biopsy specimens, and immunohistochemical staining with antibodies against the major epitopes of the type VII collagen molecule is absent or barely detectable. Milder forms of RDEB are associated with less severe biallelic mutations in the type VII collagen gene.

A single nucleotide polymorphism in the matrix metalloproteinase 1 gene promoter has been identified as a disease modifier in RDEB[22]. It is likely that additional modifying genes account for some of the inter- and intra-familial phenotypic variability observed in this and other forms of EB. There is also evidence for secondary effects from loss of protein expression in EB. For example, loss of collagen VII in RDEB fibroblasts leads to alterations in dermal matrix proteins, metalloproteinases, and transforming growth factor-β (TGF-β), which are thought to further influence keratinocyte adhesion, dermal–epidermal integrity, and dermal fibrosis[23,24].

Severe RDEB and (to a lesser extent) other forms of DEB, JEB, and Kindler EB are associated with an increased risk for the development of cutaneous SCCs. The pathogenesis of these tumors is multifactorial, and the cutaneous microenvironment plays a critical role in the initiation of carcinogenesis, tumor progression, and metastatic potential[2,25]. Increased dermal stiffness, bacterial colonization, chronic inflammation, and defects in the innate immune system contribute to the early development and aggressive nature of these tumors[23].

In self-improving DEB (previously known as bullous dermolysis of the newborn), inheritance is usually dominant and blistering is typically confined to the first 1–2 years of life[26–28]. Clinical expression coincides with a time during which type VII collagen is present primarily within basal keratinocytes in these patients' skin, rather than along the dermal–epidermal junction (see Fig. 32.1D). This suggests that there may be a temporary disruption in the transport of this protein from the keratinocyte cytoplasm to the underlying ECM.

Fig. 32.2 Localized epidermolysis bullosa simplex. A, B Bullae arising on the toes and plantar surfaces at sites of lateral or rotary traction. The majority of blisters occur in acral sites. *B, Courtesy Julie V. Schaffer, MD.*

CLINICAL FEATURES

Cutaneous Findings

All forms of inherited EB are characterized by mechanically fragile skin, erosions, and (with rare exceptions) macroscopic blisters (Figs. 32.2 & 32.3). Scarring is almost always atrophic and can occur in any subtype of EB (Fig. 32.4), including localized EBS. However, scarring is most frequent in the subtypes that are characterized clinically by generalized disease activity and ultrastructurally by disruption of the basement

Downloaded for Anonymous User (n/a) at Egyptian Knowledge Bank from ClinicalKey.com by Elsevier on March 10, 2024. For personal use only. No other uses without permission. Copyright ©2024. Elsevier Inc. All rights reserved.

Fig. 32.3 Intermediate epidermolysis bullosa simplex. Extensive blistering on the buttocks (**A**) and blistering in association with focal keratoderma on the soles (**B**) of a 2-year-old girl. *Courtesy Julie V. Schaffer, MD.*

Fig. 32.4 Dominant dystrophic epidermolysis bullosa. A, B Erosions, scarring and milia on the fingers. Note the partial (**A**) to almost complete (**B**) loss of the nails. **C** A discrete area of scarring on the elbow with blisters, crusting, and milia. *B, Courtesy Julie V. Schaffer, MD.*

membrane, particularly the lamina densa (Fig. 32.5). Whereas scarring is estimated to occur in only 15% of patients with localized EBS, it is present in essentially every patient with RDEB[29]. Other cutaneous findings that have similar variations in frequency across the major types and subtypes of EB include dystrophic or absent nails (see Fig. 32.4), milia, and scarring alopecia of the scalp.

Some cutaneous findings have diagnostic implications (Fig. 32.6)[13]. *Reticulated hyperpigmented macules* distinguish a rare subtype of EBS termed EBS with mottled pigmentation. *Grouped ("herpetiform") blisters*, often in an arcuate (Fig. 32.7) or polycyclic array, are highly characteristic of severe EBS, which is also associated with the gradual development of a diffuse palmoplantar *keratoderma* (Fig. 32.8). *Migratory circinate erythema* with vesiculation of the advancing edge has been described in patients with EBS caused by a frameshift mutation that leads to an elongated keratin 5 protein. *Excessive or exuberant granulation tissue*, usually in a symmetric distribution involving the perioriﬁcial areas, skin folds, upper back, nape of the neck, and periungual areas, is typical of severe JEB (Fig. 32.9). *Extremely pruritic papules* that can coalesce into a linear arrangement on the lower extremities, are characteristic of DEB pruriginosa (Fig. 32.10).

Distribution of skin disease activity is also useful in the subclassification of EB[29,30], although the pattern of involvement tends to be less distinctive in infants than in adults. Patients with the "inversa" subtypes of JEB and RDEB experience severe disease activity primarily in intertriginous areas such as the axillae and inguinal creases. In contrast, patients with localized JEB have involvement mainly in acral sites. Individuals with localized DEB may have lesions almost exclusively on the shins (previously referred to as pretibial DEB). A rare

Downloaded for Anonymous User (n/a) at Egyptian Knowledge Bank from ClinicalKey.com by Elsevier on March 10, 2024. For personal use only. No other uses without permission. Copyright ©2024. Elsevier Inc. All rights reserved.

subtype previously known as RDEB centripetalis initially features acral blistering, followed by slow progression of disease activity toward the trunk over the years.

Extracutaneous Findings

The molecular defects that affect the skin in patients with EB may also lead to manifestations in other tissues with an epithelial lining or surface, including the eye, oral cavity, and gastrointestinal, genitourinary, and respiratory tracts[31–36]. Major extracutaneous complications of EB are summarized in Table 32.2[31–33]. Although exceptions exist, extracutaneous involvement occurs most frequently in RDEB and JEB, and it can result in blisters, erosions, ulcers, and scarring. Rare subtypes of JEB and EBS present at birth with *pyloric atresia* as well as skin fragility and blistering[35]. In other forms of EB, extracutaneous disease may become apparent as early as the first few months of life. Repeated blistering of the *external eye* can result in neovascularization and blindness[34]. Chronic involvement of the *esophagus* leads to scarring, stricture formation and, rarely, even complete obstruction[35]. Involvement of the *small intestine* presents with chronic malabsorption, whereas disease activity within the *large intestine* tends to produce constipation and painful anal fissures or strictures. Recurrent *genitourinary tract* blistering may result in urethral or ureterovesical

Fig. 32.7 Severe epidermolysis bullosa simplex. Clustered vesicles in an arcuate array on the thigh of this child. *Courtesy Julie V. Schaffer, MD.*

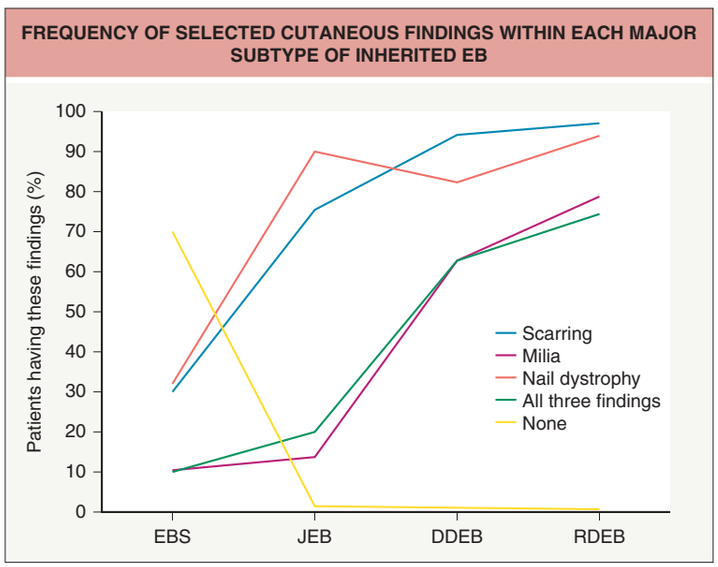

Fig. 32.5 Frequency of selected cutaneous findings within each major subtype of inherited epidermolysis bullosa (EB). Note the increasing frequency from localized EB simplex (EBS) to recessive dystrophic EB (RDEB). JEB, junctional EB; DDEB, dominant dystrophic EB.

Fig. 32.8 Severe epidermolysis bullosa simplex. Diffuse palmar keratoderma in an adult.

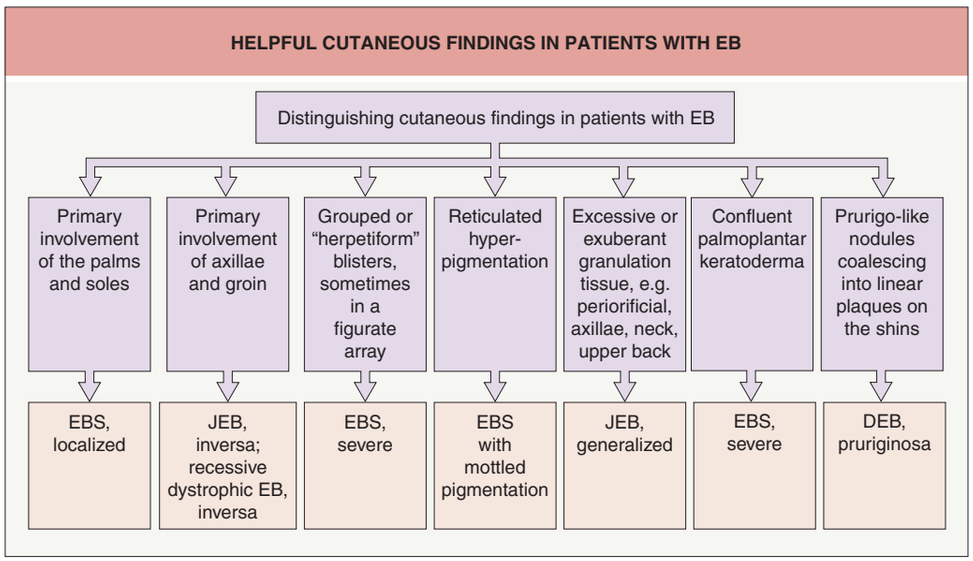

Fig. 32.6 Helpful cutaneous findings in patients with epidermolysis bullosa (EB). DEB, dystrophic EB; EBS, EB simplex; JEB, junctional EB.

Downloaded for Anonymous User (n/a) at Egyptian Knowledge Bank from ClinicalKey.com by Elsevier on March 10, 2024. For personal use only. No other uses without permission. Copyright ©2024. Elsevier Inc. All rights reserved.

Fig. 32.9 Severe junctional epidermolysis bullosa. A Blisters on the elbow and large areas of denuded skin; note the bright red color in the axilla and groin. **B** Blisters and large erosions on the abdomen of an infant. *B, Courtesy Julie V. Schaffer, MD.*

Fig. 32.10 Dystrophic epidermolysis bullosa pruriginosa. Prurigo-like papulonodules coalescing into linear plaques on the shin as a consequence of chronic scratching.

MAJOR EXTRACUTANEOUS COMPLICATIONS OF EPIDERMOLYSIS BULLOSA		
	EB subtype(s) most commonly affected	
Complication	**≥50% of patients**	**<50% of patients**
Eyes		
Corneal blisters, ulcers and scarring	Sev-RDEB	Sev-JEB >intermed-RDEB, inv-RDEB, intermed-JEB
Ectropion formation		Sev-JEB; Kindler EB
Oral cavity and upper airway (excluding blisters)		
Microstomia	Sev-RDEB	Sev-JEB, inv-RDEB
Enamel hypoplasia	JEB (all subtypes)	
Excessive caries and premature loss of teeth	Sev-RDEB, sev-JEB	
Tracheolaryngeal stenosis	Sev-JEB	Intermed-JEB
Gastrointestinal tract		
Esophageal strictures	Sev-RDEB, inv-RDEB	Intermed-RDEB, Kindler EB > sev-JEB
Pyloric atresia	JEB-PA, EBS-PA	
Malnutrition/failure to thrive	Sev-RDEB, sev-JEB	Intermed-JEB
Severe constipation	Sev-RDEB	Sev-JEB, sev-EBS
GERD	RDEB	JEB, sev-EBS
Colitis		Kindler EB, sev-RDEB
Genitourinary tract		
Urethral meatal stenosis		Sev-RDEB, sev-JEB, Kindler EB
Chronic renal failure*		Sev-RDEB
Hydroureter and hydronephrosis		JEB-PA, sev-JEB
Nephrotic syndrome	JEB-ILD/ nephrotic	Sev-JEB
Heart		
Dilated cardiomyopathy		Sev-RDEB > JEB, intermed-RDEB
Musculoskeletal system		
Pseudosyndactyly	Sev-RDEB	Intermed-RDEB, Kindler EB
Osteoporosis or osteopenia	Sev-RDEB	Sev-RDEB, sev-JEB
Muscular dystrophy	EBS-MD	
Bone marrow		
Severe multifactorial anemia	Sev-RDEB, sev-JEB	
*Causes include renal amyloidosis and glomerulonephritis.		

Table 32.2 Major extracutaneous complications of epidermolysis bullosa (EB). EBS, EB simplex; GERD, gastroesophageal reflux disease; intermed, intermediate; sev, severe; ILD, interstitial lung disease; inv, inversa; JEB, junctional EB; MD, muscular dystrophy; PA, pyloric atresia; RDEB, recessive dystrophic EB.

strictures; if persistent, the latter may eventuate in ureteric reflux and hydronephrosis. *Tracheolaryngeal* blistering and associated soft tissue edema, seen most often in infants and young children with severe JEB, may lead to potentially fatal acute airway obstruction[36]. JEB with respiratory and renal involvement is a rare subtype associated with severe interstitial lung disease.

Dental enamel hypoplasia, which occurs exclusively in JEB, is associated with pitting of the surfaces of primary and permanent teeth[37,38]. If untreated, affected individuals lose teeth during childhood due to excessive caries[39]. *Severe caries* and tooth loss also occur in severe RDEB, likely resulting from impaired clearance of food from the mouth and poor dental hygiene in the setting of intraoral injury and scarring, ankyloglossia, and microstomia.

Pseudosyndactyly ("mitten" deformities) of the hands and feet primarily affects patients with RDEB, especially severe RDEB, although it occasionally occurs to a lesser degree in DDEB and JEB[40] (Fig. 32.11B & C). Initially presenting as proximal web formation between adjacent digits, the digits may eventually become totally fused and

Downloaded for Anonymous User (n/a) at Egyptian Knowledge Bank from ClinicalKey.com by Elsevier on March 10, 2024. For personal use only. No other uses without permission. Copyright ©2024. Elsevier Inc. All rights reserved.

Fig. 32.11 Severe recessive dystrophic epidermolysis bullosa. A Area on the neck with chronic and recurrent wounds in a 7-year-old child. **B** Early proximal interdigital web formation together with atrophic scarring and loss of nails in a 5-year-old girl. **C** Partial "mitten" deformities of the hands in an older child. *A, B, Courtesy Julie V. Schaffer, MD.*

Fig. 32.12 Squamous cell carcinoma. Large squamous cell carcinoma on the ankle of a 21-year-old man with severe recessive dystrophic epidermolysis bullosa. *Courtesy Julie V. Schaffer, MD.*

encased by scar tissue. Lack of mobility leads to progressive bone resorption and muscular atrophy, and hand function is severely compromised.

Osteoporosis, detectable by dual-emission X-ray absorptiometry (DEXA) scanning, is common in severe RDEB and severe JEB. Radiographs may demonstrate vertebral crush fractures in severe cases. EBS due to plectin deficiency is associated with mild to severe *muscular dystrophy*. Although the muscle disease presents during infancy in some patients, weakness often develops insidiously during later childhood or even early adulthood in those who are less severely affected.

Chronic renal failure occasionally develops in patients with severe forms of EB, most notably severe RDEB, which is associated with a ~10% risk of death from renal failure by age 35 years[41]. Renal disease may result from untreated outflow obstruction, glomerulonephritis, secondary systemic amyloidosis, or IgA nephropathy. *Nephrotic syndrome* associated with altered expression of laminin isoforms in renal basement membranes has been reported in an infant with generalized JEB and it occurs congenitally as a result of integrin α_3 mutations in JEB with respiratory and renal involvement. A small subset of patients with severe forms of EB, especially RDEB, develop potentially fatal dilated *cardiomyopathy*[42]. Although as yet unproven, selenium or carnitine deficiency may be a contributing factor.

Although it was a common occurrence several decades ago, potentially lethal bacterial sepsis is now relatively rare in inherited EB[43], presumably due to improved wound care and the availability and judicious use of broad-spectrum antibiotics. When sepsis does occur in EB, it tends to affect infants with severe disease[44]. In contrast, failure to thrive is still common among infants with severe JEB and may lead to death.

Cutaneous Malignancies

A major complication, usually of RDEB, is the development of multiple cutaneous SCCs[45,46]. These tumors most often arise in chronic non-healing wounds or hyperkeratotic lesions (Fig. 32.12). Histologically, they are usually well differentiated. However, the borders of the lesions are often indistinct and they are difficult to completely excise, with a tendency to recur locally. In addition, SCCs in EB patients frequently metastasize and are strikingly unresponsive to chemotherapy or radiotherapy. Indeed, they represent the leading cause of death in EB at or after mid-adolescence, with death from an SCC of cutaneous origin occurring in most patients within 5 years of the diagnosis of their first SCC[44]. These tumors occur primarily in RDEB, especially when severe, although SCCs can also develop in adults with other forms of DEB, JEB, and Kindler EB. The cumulative risk of at least one SCC in patients with severe RDEB is 7.5% by age 20 years but rises to 68%, 80%, and 90% by ages 35, 45, and 55 years, respectively[33]. In contrast, the risk of SCC in other forms of RDEB is <25% by age 45 years[44].

Melanoma occurs in a small number of children with severe RDEB, with a cumulative risk of 2.5% by the age of 12 years[43]. Although this is a relatively infrequent complication, careful surveillance during childhood is indicated. Children with EB, in particular those with intermediate JEB, can develop large, irregularly shaped, darkly pigmented melanocytic nevi ("EB nevi") (Fig. 32.13) that clinically resemble melanoma, although they are histologically and biologically benign. A large size from the onset rather than a relatively slow horizontal expansion is a clue to the diagnosis of these EB-associated nevi.

Downloaded for Anonymous User (n/a) at Egyptian Knowledge Bank from ClinicalKey.com by Elsevier on March 10, 2024. For personal use only. No other uses without permission. Copyright ©2024. Elsevier Inc. All rights reserved.

APPROACH TO DIAGNOSIS

Patients with EB are classified on the basis of the clinical phenotype, mode of inheritance, ultrastructural level of blister formation, antigenic profile in the skin, and underlying genetic defect[2,29,47]. Although skin findings play an important role in determination of the EB phenotype, different subtypes of EB have considerable overlap in their cutaneous manifestations. In addition, the severity, distribution, and type of skin findings in an individual patient may change over time, such as evolution from generalized to localized blistering (or the opposite) or delayed development of sequelae such as exuberant granulation tissue, scarring, and nail dystrophy[1,29].

Fig. 32.13 Large acquired melanocytic nevus at a site of blistering in a teenage girl with junctional epidermolysis bullosa. *Courtesy Julie V. Schaffer, MD.*

Standard light microscopy has no role in the diagnosis of classic forms of inherited EB, since it may be difficult to distinguish between even lower intraepidermal and subepidermal blister formation, let alone between intra-lamina lucida (i.e. JEB) and sublamina densa (i.e. DEB) types, without more sophisticated staining techniques[47]. The diagnostic tests employed for EB include immunofluorescence antigen mapping (IFM), transmission electron microscopy (TEM), and increasingly genetic analysis[47]. TEM can define the ultrastructural level of blister formation and provide a quantitative and qualitative assessment of specific structures, such as basilar tonofilaments, hemidesmosomes, sub-basal dense plates, anchoring filaments, and anchoring fibrils[13,47]; however, currently it is routinely performed in only a few reference laboratories. A diagnostic algorithm is presented in Fig. 32.14.

APPROACH TO THE LABORATORY DIAGNOSIS OF EPIDERMOLYSIS BULLOSA (EB)

Approach to the laboratory diagnosis of epidermolysis bullosa (EB)

Immunofluorescence antigen mapping (IFM) &/or transmission electron microscopy (TEM) of biopsy specimen(s) from a fresh induced blister
- Preferred sites: upper inner arm just above elbow or a non-acral blister-prone area
- Apply firm pressure on intact skin with pencil eraser and rotate 180° in each direction 3–10+ times*
- Perform 3–4 mm punch biopsy at blister edge

Massively parallel (next-generation) sequencing panel with all known EB genes (see Table 54.6)

IFM using anti-BM monoclonal antibodies
- Place sample in Michel's/Zeus medium

Determine plane of cleavage
- Relative to antigens identified in a primary screening antibody panel, e.g. against laminin γ2 chain and collagen types IV, VII and XVII

Assess for abnormal expression or distribution of BM proteins
- Targeted secondary antibody panel
- *Decreased antigen expression* is most often seen in *recessive forms of EB:*

Antigen	Selected EB subtypes with absent/markedly reduced staining
Plectin	EBS with muscular dystrophy
$\alpha_6\beta_4$ integrin	JEB with pyloric atresia
Laminin 332	JEB-severe
Type XVII collagen	JEB-intermediate
Type VII collagen	RDEB-severe
Kindlin-1	Kindler EB (findings vary)

- Often *relatively normal* staining in *dominant forms of EB*, e.g. keratin 5/14 in EBS and type VII collagen in DDEB
- In active *self-improving DDEB*, *collagen VII* staining is *granular within basal keratinocytes* but reduced/absent within the BM

TEM
- Place sample in glutaraldehyde
- See Fig. 32.1

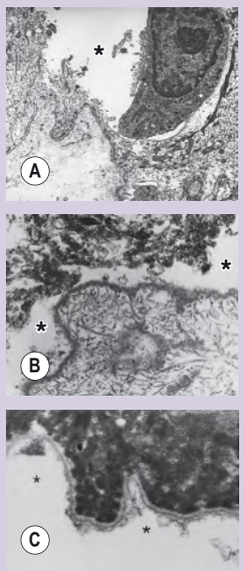

Consider genetic analysis guided by results
- Required for DNA-based prenatal/preimplantation testing

*May be more difficult to induce blisters in patients with localized EBS or DDEB

Fig. 32.14 Approach to the laboratory diagnosis of epidermolysis bullosa (EB). A Electron microscopy (EM) of an induced blister in localized EBS demonstrates skin cleavage (asterisk) within the inferior-most portion of the basilar keratinocyte. **B** EM of a spontaneous blister from a patient with the severe JEB reveals skin cleavage (asterisks) within the lamina lucida. Hemidesmosomes, sub-basal dense plates, and anchoring filaments are all absent. In contrast, anchoring fibrils are still present in normal amounts within the underlying dermis. **C** EM of the roof of a spontaneous blister from a patient with severe RDEB reveals cleavage (asterisks) beneath the level of the lamina densa. Anchoring fibrils are absent along the epidermal roof of the blister. BM, basement membrane; DDEB, dominant dystrophic EB; EBS, EB simplex; JEB, junctional EB; RDEB, recessive dystrophic EB.

Downloaded for Anonymous User (n/a) at Egyptian Knowledge Bank from ClinicalKey.com by Elsevier on March 10, 2024. For personal use only. No other uses without permission. Copyright ©2024. Elsevier Inc. All rights reserved.

Genetic analysis has become the first-line method for EB diagnosis and classification, with increasing availability and decreasing cost of massively parallel (next-generation) sequencing panels that include all known EB genes[47]. Molecular diagnosis allows more accurate genetic counseling and is required for DNA-based prenatal/preimplantation testing.

Differential Diagnosis

Although it is difficult to determine the subtype of inherited EB on the basis of clinical findings alone, the diagnosis of EB itself is usually straightforward, especially beyond early childhood. There is a limited differential diagnosis for a chronic mechanobullous disease with early onset and/or a positive family history[1,2]. Other genetic diseases that may present with blistering early in life include acantholytic erosive disorder and other skin fragility syndromes due to defects in desmosomal proteins as well as peeling skin syndromes and epidermolytic ichthyosis (see Ch. 57)[1] (Fig. 32.15A,B). Of note, the former disorders were previously categorized as forms of EBS. Genodermatoses that can be associated, at least transiently, with skin fragility or blisters and therefore potentially misdiagnosed as EB are outlined in Table 32.3. Less often, EB may be confused with acrodermatitis enteropathica, incontinentia pigmenti stage 1, pachyonychia congenita, or early lipoid proteinosis.

The differential diagnosis of blisters and erosions in neonates or young infants may also include infectious diseases (e.g. herpes simplex viral infection, staphylococcal scalded skin syndrome, bullous impetigo), sucking blisters, mastocytosis, autoimmune blistering diseases, and congenital erosive and vesicular dermatosis (see Ch. 34). Diagnostic considerations in patients with acral blistering, erosions, and ulcerations with progression to digital resorption may include congenital erythropoietic porphyria (see Table 32.3 and Ch. 49) and SAVI (*S*TING-*a*ssociated *v*asculopathy with onset in *i*nfancy [Fig. 32.15C]; see Ch. 45).

Congenital localized absence of skin (CLAS), also referred to as aplasia cutis congenita, can occur in any form of EB (see Ch. 64). In patients with EB, CLAS is distinguished by the associated skin fragility and blistering as well as its frequent location on the lower extremities (referred to as Bart syndrome), although involvement may be more widespread, especially in forms of EBS or JEB associated with pyloric atresia[48].

TREATMENT

Day-to-day management of EB revolves around the prevention of mechanical trauma, wound care, and avoidance of infection. Protective bandaging, padding over bony prominences, and soft/loose-fitting clothing can be helpful. Bathing or soaking with ~0.005% sodium hypochlorite (0.5 cup household bleach [6%–8.25% sodium hypochlorite] in a full standard bathtub) or 0.25% acetic acid (1 part white vinegar [5% acetic acid] to 19 parts water) may help to reduce bacterial colonization. Antibiotics should be used judiciously, with avoidance of chronic treatment with topical mupirocin or oral antibiotics. Problematic plantar hyperhidrosis in EBS patients may be reduced by the topical application of aluminum chloride hexahydrate, although its effect on blistering is less certain, and injection of botulinum toxin A can decrease plantar blistering and associated pain in some individuals with EBS[49].

A number of dressings are available for cutaneous wounds in EB patients (Table 32.4; see Ch. 145). As a general rule, only those that are non-adhesive or "low-tack" should be applied to EB skin. Soft silicone dressings, some of which incorporate an absorbent foam backing, are widely used. Silver-impregnated dressings may be helpful for heavily colonized or infected wounds, although long-term application should be avoided to prevent excessive systemic silver absorption and cutaneous argyria. Less expensive Vaseline®-impregnated gauze is another suitable dressing for non-infected wounds. Topical therapies under investigation include diacerein 1% cream, which downregulates production of interleukin-1β and keratin 14, thereby stabilizing the keratinocyte intermediate filament network and reducing blister formation in patients with EBS[50].

Systemic drugs that may be of benefit include tetracycline or erythromycin for EBS[51] and dupilumab, thalidomide, or cyclosporine for symptomatic relief in DEB pruriginosa[52,53]. There are few reports on the use of systemic retinoids in any form of EB, although these drugs appear to be tolerated, at least in low dosage, in patients with RDEB[54]. Whether long-term treatment with low-dose systemic retinoids would

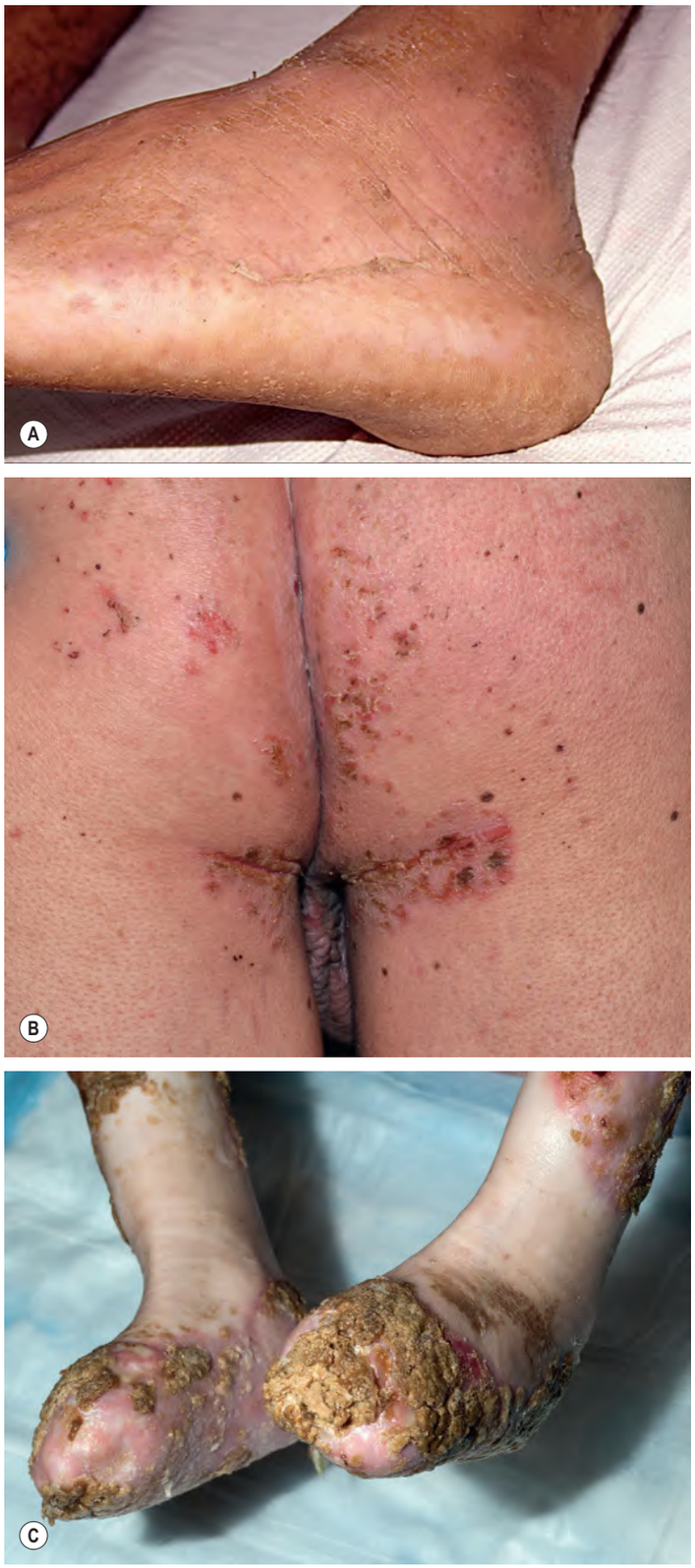

Fig. 32.15 Differential diagnosis of epidermolysis bullosa. A Acral peeling skin syndrome presenting with superficial peeling of the skin on the ankle and dorsal aspect of the foot. **B** Skin fragility–ectodermal dysplasia syndrome due to plakophilin 1 deficiency. Note the scattered erosions and crusts on the buttocks. **C** SAVI (*S*TING-*a*ssociated *v*asculopathy with onset in *i*nfancy) represents a vasculopathic genetic disorder that can result in digital resorption resembling that in recessive dystrophic epidermolysis bullosa. *A, Courtesy E. Sprecher, MD, PhD; B, Courtesy Antonio Torrelo, MD; C, Courtesy Edward Cowen, MD.*

Downloaded for Anonymous User (n/a) at Egyptian Knowledge Bank from ClinicalKey.com by Elsevier on March 10, 2024. For personal use only. No other uses without permission. Copyright ©2024. Elsevier Inc. All rights reserved.

ADDITIONAL GENODERMATOSES ASSOCIATED WITH SKIN FRAGILITY OR BLISTERS		
Disorder	**Defective protein/gene (inheritance)**	**Clinicopathologic features**
Erosive skin fragility disorders		
Skin fragility–woolly hair syndrome (DSP), skin fragility–ectodermal dysplasia syndrome (PKP1), and related conditions	Desmoplakin/*DSP*, plakophilin 1/*PKP1*, or plakoglobin/*JUP** (AR)	Erosions > blisters favor extremities (Fig. 32.15B), perioral and intertriginous fissures, focal PPK with fissures; sparse and/or woolly hair, nail dystrophy; acantholysis in skin biopsy specimens; **DSP:** follicular keratoses on extensor surfaces, variable cardiomyopathy and hoarseness; **JUP***: PPK, alopecia or curly hair, cardiomyopathy
Acantholytic erosive disorder (formerly acantholytic EBS)	Desmoplakin/*DSP* or plakoglobin/*JUP* (AR)	Generalized erosions at birth; universal alopecia; acantholysis in skin biopsy specimens; **DSP:** natal teeth, anonychia and variable cardiomyopathy; **JUP:** onycholysis and infections
Peeling skin fragility disorders		
Acral peeling skin syndrome	Transglutaminase 5 (AR)	Superficial peeling and erosions on hands and feet (see Fig. 32.15A)
EBS superficialis		
EBS superficialis	Unknown	Superficial erosions; postinflammatory hyperpigmentation; subcorneal cleavage
Hyperkeratotic skin fragility disorders		
Superficial epidermolytic ichthyosis	Keratin 2 (AD)	Mauserung phenomenon (desquamation); superficial intraepidermal blistering in skin biopsy specimens
Epidermolytic ichthyosis	Keratins 1 and 10 (AD)	Blistering primarily in the first few years of life; later, corrugated hyperkeratosis; epidermolytic hyperkeratosis in skin biopsy specimens; **keratin 1**: PPK
Connective tissue disorder with skin fragility		
Syndromic connective tissue disorder with skin fragility	Lysyl hydroxylase 3 (AR)	Predominantly acral blistering; scoliosis, joint contractures, pterygia, dysmorphic facies, ocular anomalies
Additional genodermatoses with erosions or blistering		
Congenital erythropoietic porphyria (Günther disease)	Uroporphyrinogen III synthetase (AR)	Severe photosensitivity leading to blistering, deep ulcerations and facial/digital mutilation; elevated uroporphyrin I and coproporphyrin I; red urine and teeth; hemolytic anemia
Mendes da Costa syndrome	Unknown (X-linked)	Spontaneous formation of bullae (unprovoked by trauma); atrichia; acrocyanosis; dyspigmentation; microcephaly; intellectual disability
AEC (ankyloblepharon–ectodermal dysplasia–clefting) syndrome	p63 (AD)	Ankyloblepharon; ectodermal dysplasia; cleft lip and palate; erythroderma; widespread erosions in neonates; chronic erosive scalp dermatitis; patchy alopecia

*Features overlap with those of Naxos disease (see Ch. 58).

Table 32.3 Additional genodermatoses associated with skin fragility or blisters in the differential diagnosis of epidermolysis bullosa. Additional diagnostic considerations may include other peeling skin syndromes (see Table 57.8) and pachyonychia congenita (see Chs. 58 & 71). Biallelic mutations in the genes encoding desmocollin 3 and desmoglein 3 have been implicated in hypotrichosis with recurrent skin vesicles and acantholytic oral/laryngeal blisters, respectively. AD, autosomal dominant; AR, autosomal recessive; EBS, epidermolysis bullosa simplex; PPK, palmoplantar keratoderma.

DRESSINGS FREQUENTLY USED IN PATIENTS WITH EPIDERMOLYSIS BULLOSA		
Dressing type	**Use**	**Examples®,™**
Soft silicone dressings ("low-tack")	• Suitable as primary or secondary dressings in many types of EB • May have a foam backing for mechanical protection or to wick exudate away from the wound	Mepitel, Mepilex, Mepilex Transfer, Mepilex Border
Non-adherent lipido-colloid dressings	• Suitable for primary contact	Urgotul
Hydrogel dressings	• Provide moisture to drier wounds to facilitate healing • May provide relief from pain or itch	Flexigel, Curagel, ActiForm Cool
Foam dressings	• Useful to absorb moderate amounts of wound exudate	Mepilex, Allevyn
Absorptive dressings	• Useful to absorb heavy amounts of wound exudate	Eclypse, Sorbion Sana
Silver-containing dressings	• Clinically infected or highly colonized wounds • Avoid prolonged use due to risk of silver absorption	Urgotul SSD, Mepilex AG
Other antimicrobial dressings	• Clinically infected or highly colonized wounds	PolyMem, Cutimed Sorbact, Activon Tulle, Suprasorb X + PHMB

Table 32.4 Dressings frequently used in patients with epidermolysis bullosa (EB).

help to prevent the development of SCCs in severe RDEB patients remains to be determined. The angiotensin receptor blocker losartan interferes with TGF-β signaling, which is upregulated in the skin of RDEB patients and may contribute to the risk of developing SCC. Losartan was shown to reduce cutaneous fibrosis and digital fusion in a mouse model of EB and is currently under investigation in RDEB patients[55].

Although not yet in mainstream clinical practice, translational therapeutic approaches for EB utilizing cell-, protein- and gene-based methods have been a focus of attention in recent years[2,56]. In clinical trials investigating the value of allogeneic bone marrow-derived stem cell transplantation in patients with RDEB, significant clinical responses were observed, with production of collagen VII at the dermal–epidermal junction and improved wound healing[57,58]. However, there was also

Downloaded for Anonymous User (n/a) at Egyptian Knowledge Bank from ClinicalKey.com by Elsevier on March 10, 2024. For personal use only. No other uses without permission. Copyright ©2024. Elsevier Inc. All rights reserved.

substantial associated morbidity and mortality, although ameliorated to some extent by using reduced-intensity conditioning regimens. An alternative approach has been to use intradermal[59] or intravenous[60,61] injections of allogeneic mesenchymal stem cells in patients with severe RDEB, which has led to improved wound healing as well as reduced inflammation and itch. Injections of allogeneic fibroblasts into RDEB wounds also improved wound healing in a small clinical trial[62]. In addition, intradermal and intravenous delivery of recombinant collagen VII has been explored in animal models of RDEB but not yet in human studies[63].

Gene therapy for EB is currently under investigation in several clinical trials. It was first successfully performed in a man with intermediate JEB, with *ex vivo* gene correction of autologous keratinocytes to restore laminin 332[64]. A skin equivalent was generated and grafted onto the patient's legs, with amelioration of blistering that persisted for years post-procedure. Similar approaches utilizing *ex vivo*-gene correction have subsequently been employed in a child with severe JEB, with graft coverage of ~80% of his body surface area, and patients with RDEB[65,66]. *In vivo* topical gene therapy with beremagene geperpavec (B-VEC), a non-replicating *COL7A1*-containing herpes simplex virus type 1 vector, was recently shown in a randomized placebo-controlled study to induce collagen VII expression and promote healing when applied to wounds in patients with RDEB[67]. Gene editing using technologies such as CRISPR/Cas9 and base editing to restore expression of functional proteins in EB has also been explored[68,69]. Another promising method is the use of drugs such as aminoglycoside antibiotics (e.g. topical or intravenous gentamicin) to induce read-through of nonsense mutations and improve wound healing in RDEB and JEB patients[70,71].

Revertant mosaicism in the skin of EB patients represents "natural gene therapy" that can restore wild-type function to a clone of cells, providing a model for potential gene manipulation strategies and possibly explaining the tendency for improvement with age in some subtypes of EB. Mitotic gene conversion, true back mutations, and second-site mutations that prevent a premature termination codon or restore the reading frame have been shown to reverse disease-causing type XVII collagen mutations in individuals with intermediate JEB, leading to decreased blistering in discrete areas of skin[72]. Second-site nonsense mutations have also been shown to abrogate blistering by silencing a dominant-negative keratin 14 allele in those with severe EBS, and revertant mosaicism has also been observed in RDEB patients. Furthermore, patients with intermediate JEB have had successful local treatment with autologous grafts harvested from areas of revertant skin[73].

Strategies for the medical and surgical management of long-term complications of EB are outlined in Table 32.5[33,74–76]. Multidisciplinary clinics can provide care and support for the wide range of needs that patients with EB and their families have. Families can also obtain helpful information from several support group websites, in particular www.debra.org and www.debra-international.org.

KINDLER EPIDERMOLYSIS BULLOSA

Synonyms: ▪ Kindler syndrome ▪ Kindler–Weary syndrome ▪ Bullous acrokeratotic poikiloderma of Kindler and Weary ▪ Hereditary acrokeratotic poikiloderma

Introduction

Kindler EB is a rare autosomal recessive genodermatosis that features skin fragility and photosensitivity during early life as well as progressive poikiloderma, cutaneous atrophy, and mucosal inflammation[2,77–79].

History

In 1954, Theresa Kindler described a patient with acral blistering and photosensitivity during infancy, followed later in life by progressive poikiloderma and atrophy. Twenty years later, Weary reported ten members of a single family with similar findings in addition to widespread atopic dermatitis during early childhood and keratotic papules over the joints of the arms and legs that appeared in childhood and persisted indefinitely. Oral involvement and other mucosal manifestations were subsequently emphasized[77–81].

Pathogenesis

Kindler EB is characterized ultrastructurally by basement membrane reduplication and mixed planes of cleavage that can be within basal keratinocytes, through the lamina lucida, and/or below the lamina densa[2,82]. It results from mutations in the FERM domain-containing kindlin-1 gene (*FERMT1*) which encodes kindlin-1, a component of focal adhesions that connect actin filaments in basal keratinocytes to the underlying ECM[81–84] (see Ch. 28). Through integrin-mediated signaling, kindlin-1 affects the shape, polarity, adhesion, proliferation, and motility of keratinocytes[78]. There is also evidence that kindlin-1 has a role in regulating cutaneous epithelial stem cell homeostasis, with loss of kindlin-1 leading to increased risk of skin cancer as well as cutaneous atrophy due to stem cell exhaustion and premature senescence of keratinocytes[84].

Clinical Features

Erosions are occasionally present at birth, most often on the forearms and shins, and blistering during infancy is most prominent on the hands and feet. In contrast to other forms of EB, skin fragility tends to decrease considerably during childhood. Photosensitivity manifesting as an increased susceptibility to sunburn also improves over time. Reticulated hyperpigmentation and telangiectasias begin to develop in sun-exposed areas during childhood, and after puberty these findings spread to sun-protected sites. A characteristic feature in adult patients with Kindler EB is poikiloderma (Fig. 32.16A), which persists throughout life. Tissue paper-like atrophy is frequently seen, particularly on the dorsal surfaces of the hands and feet (Fig. 32.16 B,C), and mild webbing of the digits (see Fig. 32.16C) and palmoplantar hyperkeratosis may also be evident. Eczematous dermatitis, typically beginning during infancy and resolving by early childhood, occurs in some patients.

Patients with Kindler EB often have erosive gingivitis and poor dentition. Mucosal involvement may result in intraoral and corneal scarring, ectropion, colitis, and strictures of the esophagus, urethra, vagina, and anus. Patients have an increased risk of SCC of the lip and oral mucosa as well as acral skin[81].

Pathology

In older patients, skin biopsy specimens show the typical changes of poikiloderma, including epidermal atrophy, vacuolization of the basal cell layer, variable epidermal melanin content, dermal melanophages, and capillary dilation. Immunostaining of skin biopsy specimens with anti-kindlin-1 antibodies often demonstrates a marked reduction or absence of this protein[82]. Ultrastructural findings are noted above.

Differential Diagnosis

The predominantly acral distribution of the blisters and associated atrophy and photosensitivity distinguish Kindler EB from other forms of EB, although a form of JEB characterized by progressive cutaneous atrophy similar to that in Kindler EB has been described[85]. As poikiloderma becomes apparent during early childhood, the differential diagnosis may include Rothmund–Thomson syndrome and other entities outlined in Table 63.9.

Treatment

Management is akin to other forms of EB, with the addition of sun protection and assiduous oral hygiene.

Additional figures available in our eBook (see inside front cover for access code).

Downloaded for Anonymous User (n/a) at Egyptian Knowledge Bank from ClinicalKey.com by Elsevier on March 10, 2024. For personal use only. No other uses without permission. Copyright ©2024. Elsevier Inc. All rights reserved.

MANAGEMENT OF LONG-TERM COMPLICATIONS OF EPIDERMOLYSIS BULLOSA		
Complication	**Prevention and monitoring/detection**	**Management**
Oral and gastrointestinal		
Excessive caries	• Diligent oral hygiene • Antiseptic and fluoride mouthwashes • Periodic evaluation and cleaning by a dentist	• Restorative dentistry
Microstomia		• Physical therapy • "Mouth expanding" devices
Oral ulceration		• Topical antiseptics, topical NSAIDs, barrier preparations (e.g. sucralfate suspension)
Esophageal strictures	• Evaluate dysphagia with contrast studies	• Dietary modification (soft foods/purées, caloric supplementation) • Fluoroscopically guided balloon dilatation; repeated procedures are often required • In severe and recalcitrant cases, surgical options include colonic interposition
Gastroesophageal reflux disease		• Proton pump inhibitors, H_2 blockers, prokinetic agents (e.g. metoclopramide, domperidone [not available in the US])
Constipation	• Ensure adequate fluid intake and dietary fiber	• Osmotic laxatives (e.g. containing polyethylene glycol), mineral oil • Avoid suppositories and enemas
Nutritional		
Growth retardation/inadequate intake to meet nutritional needs	• Monitor height, weight and body mass index • Periodically assess serum zinc, selenium, iron, vitamin D, and carnitine levels (e.g. yearly) • Oral supplements to optimize intake of calories, protein, vitamins, and minerals	• Consider gastrostomy feedings
Hematologic		
Anemia due to iron deficiency and chronic inflammation	• Monitor CBC and measures of iron stores	• Iron supplementation (oral or IV) • Consider erythropoietin or darbepoetin alpha • Consider blood transfusion if hemoglobin ≤7–8 g/dl and/or symptomatic
Genitourinary and renal		
Urinary outflow obstruction (e.g. urethral or ureteral strictures)	• Consider annual ultrasound of the urinary tract and urodynamic studies (especially for JEB)	• Dilatation procedures as needed to treat obstruction • Avoid unnecessary instrumentation
Renal disease (e.g. hydronephrosis, post-infectious glomerulonephritis, renal amyloidosis, IgA nephropathy)	• Blood urea nitrogen & serum electrolyte levels, urinalysis and blood pressure evaluation every 6 months in RDEB patients • Adequately treat streptococcal infections	• Hemodialysis or peritoneal dialysis if renal failure develops
Musculoskeletal		
Osteopenia and osteoporosis	• Annual DEXA scan and spinal radiographs beginning at age 5 years in RDEB and JEB patients • Calcium and vitamin D supplementation	• Consider IV bisphosphonate therapy
Pseudosyndactyly of hands/feet	• Cushioned splints on hands/forearms and individual wrapping of fingers in RDEB patients	• Surgery to release contractures and webbing
Oncologic		
Cutaneous squamous cell carcinoma	• Periodic total-body skin examinations; for RDEB patients, approximately every 3–6 months beginning at age 10 years and every 3 months after age 16 years • Biopsy or monitor non-healing ulcers (see Fig. 32.13) • Consider taking serial photographs	• Excision ± skin grafting (sometimes amputation); consider MRI to assess extent of local disease • Consider staging with CT, PET-CT, sentinel lymph node biopsy • Use of EGFR and immune checkpoint inhibitors for advanced disease has been reported
Ocular		
Chronic complications include corneal scarring, symblepharon, ectropion	• Periodic ophthalmologic evaluation for patients with eye involvement • Lubricating eye drops	• Surgical procedures, e.g. division of symblepharon, amniotic membrane transplantation
Cardiac		
Dilated cardiomyopathy	• Consider annual echocardiography beginning in late childhood for RDEB patients	• Medical management • Supplement selenium and carnitine if deficient
Psychological and psychiatric		
Disrupted family unit (e.g. via divorce)	• Consider family counseling, support groups	• Psychological/family counseling
Depression and suicidal ideation/attempts	• Consider psychological counseling, support groups	• Psychiatric evaluation, antidepressant therapy

Table 32.5 Management of long-term complications of epidermolysis bullosa (EB)[33,74,75]. CBC, complete blood count; CT, computed tomography; EGFR, epidermal growth factor receptor; JEB, junctional EB; MRI, magnetic resonance imaging; NSAID, nonsteroidal anti-inflammatory drug; PET, positron emission tomography; RDEB, recessive dystrophic EB.

Downloaded for Anonymous User (n/a) at Egyptian Knowledge Bank from ClinicalKey.com by Elsevier on March 10, 2024. For personal use only. No other uses without permission. Copyright ©2024. Elsevier Inc. All rights reserved.

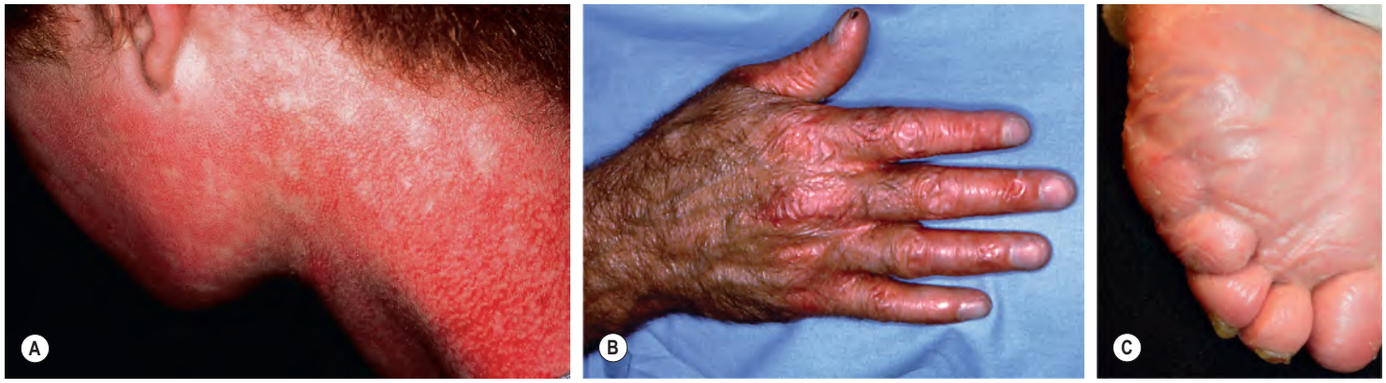

Fig. 32.16 Kindler epidermolysis bullosa. A Poikiloderma of the face and neck with "skip" areas. **B** Erythema and atrophy on the dorsal hand. **C** Progressive syndactyly of fourth and fifth toes in an adult. Note the near absence of dermatoglyphics. This patient also had ectropion and urethral strictures. *C, Courtesy Jean L. Bolognia MD.*

eFig. 32.1 Epidermolysis bullosa simplex. Blistering and focal keratoderma on the soles of a 4-year-old boy. *Courtesy Julie V. Schaffer, MD*.

eFig. 32.2 Severe epidermolysis bullosa simplex. Clustered vesicles in an arcuate array on the arm of this child. *Courtesy Julie V. Schaffer, MD*.

eFig. 32.3 Dominant dystrophic epidermolysis bullosa. A, B Erosions, scarring, and milia on the digits, as well as partial shedding of a toenail (**A**).

Downloaded for Anonymous User (n/a) at Egyptian Knowledge Bank from ClinicalKey.com by Elsevier on March 10, 2024. For personal use only. No other uses without permission. Copyright ©2024. Elsevier Inc. All rights reserved.

eFig. 32.4 Recessive dystrophic epidermolysis bullosa. Scarring with fusion of toes and ulcerations at sites of previous bullae. *Courtesy M. Joyce Rico, MD.*

eFig. 32.5 Skin fragility–ectodermal dysplasia syndrome due to plakophilin 1 deficiency. A Palmar keratoderma with accentuation in areas of friction and fissuring. **B** Erosions in intertriginous zones and multiple hemorrhagic crusts. *Courtesy Antonio Torrelo, MD.*

eFig. 32.6 Kindler epidermolysis bullosa. Wrinkling due to atrophy and fusion between the fourth and fifth toes. This patient also had ectropion and urethral strictures. *Courtesy Jean L. Bolognia, MD.*

Downloaded for Anonymous User (n/a) at Egyptian Knowledge Bank from ClinicalKey.com by Elsevier on March 10, 2024. For personal use only. No other uses without permission. Copyright ©2024. Elsevier Inc. All rights reserved.